



**University of
Sunderland**

Steel, D, Suleman, J, Murphy, D.C., Dodds, S and Rees, Jon
(2018) Optic disc pit maculopathy: a two-year nationwide
prospective study. *Ophthalmology*, 125 (11). pp. 1757-1764.
ISSN 0161-6420

Downloaded from: <http://sure.sunderland.ac.uk/id/eprint/9460/>

Usage guidelines

Please refer to the usage guidelines at
<http://sure.sunderland.ac.uk/policies.html> or alternatively contact
sure@sunderland.ac.uk.

1 **Title:** Optic disc pit maculopathy: a two-year nationwide prospective population
2 study.

3

4 **Authors:**

5 David HW Steel MBBS, FRCOphth^{1,2}

6 Javid Suleman MBChB, FRCOphth¹

7 Declan C Murphy²

8 Anna Song²

9 Steve Dodds MSC¹

10 Jon Rees BSc MBBS³

11

12 **Affiliations:**

13 1 Sunderland Eye Infirmary, Sunderland, UK

14 2 Institute of Genetic Medicine, Newcastle University, Newcastle Upon Tyne, UK

15 3 School of Psychology, Faculty of Health Sciences and Well Being, University of
16 Sunderland, Sunderland, UK

17

18 **Correspondence to:**

19 Mr D Steel

20 Sunderland Eye Infirmary

21 Queen Alexandra Road

22 Sunderland

23 UK

24 David.steel@ncl.ac.uk

25 Telephone: +441915699065

26 Fax +441915699060

27

28 **Additional information:** All authors meet the four criteria set by the International
29 Committee of Medical Journal Editors and hence justify their authorship in this
30 article.

31 **Financial support:** The study was supported by a grant from the British and Eire
32 Association of Vitreoretinal Surgeons and Sunderland Eye Infirmary to which we are
33 both very grateful. The sponsor or funding organization had no role in the design or
34 conduct of this research.

35 **Conflict of interest:** D Steel declares that he has acted as a consultant to Alcon and
36 received research funding from Bayer in projects unrelated to this study. No other
37 authors have any disclosures to make.

38 **Running head:** Optic disc pit maculopathy

39

40 **Address for reprints:**

41 Sunderland Eye Infirmary, Sunderland, UK

42 **Abstract**

43 Purpose: To identify the incidence, presenting features, treatment and clinical course
44 of Optic Disc Pit Maculopathy (ODPM) in the United Kingdom (UK).

45 Design: A 2-year nationwide prospective population study.

46 Subjects: All new incident cases of ODPM presenting to UK ophthalmologists using
47 the British Ophthalmic Surveillance Unit monthly reporting system.

48 Methods: All reporting ophthalmologists were sent an initial questionnaire requesting
49 data on previous medical and ophthalmic history, presentation details, investigation
50 findings and management. A further questionnaire was sent at 12-month post-
51 diagnosis to ascertain further outcome data.

52 Main Outcome Measures: Visual acuity at initial presentation, at 1-year and after any
53 intervention. Foveal involvement and optical coherence tomography (OCT) findings,
54 including retinal layers affected, and the location and size of the optic disc pit.

55 Management including observation, vitrectomy and associated procedures.

56 Results: There were 74 confirmed new cases giving an annual incidence of
57 approximately 1 per 2 million. Complete data were available on 70 patients (70 eyes)
58 at baseline and 68 after 1 year. There were 35 (50%) female patients with a mean
59 age of 35 years (range 3-82). Visual acuity at baseline ranged from 6/5 to hand
60 movements. In 43 (61%) cases subretinal fluid (SRF) was present whereas 27(39%)
61 had intraretinal (IRF) fluid only. The presence of SRF was associated with worse
62 vision and foveal involvement. Of the 53 eyes initially observed with 1-year follow-up,

63 10 (19%) deteriorated and 9 (16%) improved on OCT; eyes with SRF were more
64 likely to worsen and those without SRF were more likely to improve. 15 (21%) of the
65 70 patients at baseline had primary surgery and a further 10 had deferred surgery
66 within 1 year of presentation. 19 of these 25 eyes (75%) showed anatomical success
67 with a dry fovea at 1 year of follow-up. 15 (60%) had a greater than a 0.1 logMAR
68 improvement in Va.

69 Conclusion: The incidence and presenting features of ODPM were defined. Cases
70 with SRF had worse vision and were more likely to deteriorate than cases with IRF
71 only. Surgery was anatomically successful in 75% of cases. Cases without SRF
72 tended to remain stable with observation.

73

74 **Introduction**

75 Congenital optic disc pits (ODP) are a rare abnormality of the optic nerve head and
76 occur with an estimated prevalence of 2 in 10,000.^{1, 2} Upon fundoscopic
77 examination, they usually appear as a grey, round or oval depression in the temporal
78 segment of the disc and are often associated with strands of attached and
79 condensed vitreous at the retinal surface.^{3, 4} Histopathologically, they demonstrate a
80 herniation of dysplastic retinal tissue into a collagen-rich excavation that can extend
81 into the subarachnoid space through a defect in the lamina cribrosa.^{5, 6} Their origin is
82 uncertain and they are not typically associated with other systemic or eye
83 abnormalities.^{7, 8} As an isolated finding they are usually asymptomatic, however an
84 estimated 25-75% of patients develop an associated serous detachment and/or
85 retinoschisis of the central macula at some point in their lives^{3, 9}: this pathological
86 scenario is termed optic disc pit maculopathy (ODPM). Although the subject of many

87 case reports and cases series, there have been no population-based studies
88 investigating ODPM. As such, the clinical features at presentation and its clinical
89 course following both surgery and observation have yet to be reported using a
90 consecutive large unbiased cohort.

91 In this study we sought to determine the incidence, presenting features, clinical
92 course and management of patients presenting with ODPM in the United Kingdom
93 (UK) over a two-year period.

94

95 **Method**

96 A population-based study was performed with prospective case ascertainment using
97 the British Ophthalmological Surveillance Unit (BOSU) monthly reporting card
98 system.¹⁰ The BOSU was established to aid the investigation of rare eye conditions
99 with public health or scientific importance. It involves all independently practising
100 ophthalmologists in the UK using a database that is maintained and updated by the
101 Royal College of Ophthalmologists. Each month these clinicians are sent a card,
102 detailing approximately 5 nominated conditions, and they are asked to report any
103 new incident cases. From May 2014 to May 2016 ophthalmologists were asked to
104 report all new patients presenting with a congenital ODP with any associated intra-
105 or subretinal fluid extending from the pit into the juxtapapillary retina, regardless of
106 symptoms. An ODP was defined as a localised round or oval depression within the
107 optic disc head. We excluded cases with other congenital optic disc abnormalities
108 (e.g. Morning Glory) as well as acquired optic disc pits. Cases with choroidal
109 colobomas were included if the coloboma was entirely separate from the disc.

110 Once new cases were notified to the BOSU, every reporting ophthalmologist was
111 sent a detailed questionnaire by the study investigators. These questionnaires
112 requested them to provide data for each case, including their previous medical and
113 ophthalmic history, presenting clinical symptoms and signs, including signs on
114 optical coherence tomography (OCT), and the initial management provided to the
115 patient. (see supplementary file 1) The clinical features requested include a
116 reference congenital disc pit image with which to compare the ODP size, as well as
117 OCT images to aid the reporting ophthalmologists in defining the distribution of any
118 associated intraretinal or subretinal fluid. (Figure 1) Details concerning patient
119 outcomes were obtained from follow-up questionnaires sent to the reporting
120 ophthalmologists 12 months after the initial diagnosis as well as 12 months after the
121 last intervention. (see supplementary file 2) Ophthalmologists who did not return the
122 questionnaires received reminder letters 2 months after the initial questionnaire was
123 sent. If there was still no reply, further follow-up emails were sent to non-responders.

124

125 To maximise case reporting, the study was publicised widely in special interest
126 groups in the UK, including the British and Eire Association of Vitreoretinal Surgeons
127 and national meetings including the Royal College of Ophthalmologists annual
128 congress. BOSU monitors monthly reporting card returns and encourages
129 participation by providing the participants with regular study updates and return
130 rates. The overall BOSU card return rate in our study averaged 76% over the 24-
131 month period. (Personal communication Barny Foot) To avoid duplicate case
132 reporting, returns were investigated when cases were reported from the same
133 centre, and cases referred to other centres from the original reporting clinician were
134 cross checked to ensure notification from both centres had or had not occurred.

135

136 The population incidence was calculated using the estimated UK (England, Scotland,
137 Wales, and Northern Ireland) population (65.11 million) at the midpoint of the study
138 period.¹¹

139

140 The protocol was reviewed and refined by the BOSU steering committee and the
141 questionnaires were trialled by 8 retinal specialist clinicians prior to the study's onset.
142 Ethical approval was obtained for the UK Research Ethics committee (NRES
143 Committee West Midlands - Solihull 14/WM/0054). Informed consent was not
144 required by individual patients but the study adhered to the principles of the
145 Declaration of Helsinki and UK Caldicott guidelines.

146

147

148 **Statistical analysis**

149 Descriptive and statistical analysis was performed using SPSS statistical package
150 (SPSS v24). All visual acuities were converted to the logarithm of the minimal angle
151 of resolution (logMAR) for analysis. Baseline and follow up variables are presented
152 in terms of mean, standard deviation and range when normally distributed, and
153 percentages as appropriate. Visual stability was defined as visual acuity +/- 0.1
154 logMAR, with worsening or improvement being a greater than 0.1 logMAR change.
155 Anatomical success with surgery was defined as a dry fovea on OCT at 1 year
156 following surgery. Correlations between variables of continuous data were assessed
157 using Pearson's correlation coefficient and comparisons between categorical data
158 were performed using Chi-squared and Fishers tests as appropriate. Differences
159 among variables were assessed with two-sided t tests and one-way ANOVA where

160 appropriate for continuous data, and chi-squared tests when the data were
161 categorical. Stepwise multiple regression examined the relationship between
162 numerous variables. Statistical significance was described when a p-value of 0.05 or
163 less was obtained.

164

165 **Results**

166 During the two-year study period, a total of 111 patients (111 eyes) were reported to
167 the BOSU. In 9 cases there was no reply to the request for additional information
168 and thus a data return rate of 92% was attained in our study. We identified sixteen
169 cases that were duplicates and 12 false reports occurring due to other conditions
170 (e.g. pit without any retinal fluid, morning glory abnormality, acquired pits and
171 examples presented outside the reporting period) or other reporting errors. After
172 these reports were excluded, we were left with a total of 74 true cases of ODPM.

173

174 The incidence of ODPM could be calculated from the data obtained. It equates to an
175 incidence of 5.7 per 10 million per annum, which is equivalent to approximately 1 in 2
176 million per annum of the UK population. In 4 of the 74 confirmed cases, although
177 having confirmed that they identified a true case, the reporting ophthalmologist had
178 lost the patients details and hence were unable to complete the questionnaire; this
179 resulted in a final count of 70 cases with complete baseline data from the two-year
180 period. One-year follow-up questionnaires were returned on 68 of these initial 74
181 (92%) cases.

182

183 **Baseline findings**

184

185 Baseline features are presented in table 1. The mean age of the 70 patients with full
186 baseline data was 35 years old (range 3-82 years old), and 35 (50%) were female.
187 65 (93%) self-described themselves as “White British or other”, 1 as “Asian Indian”, 2
188 as “Black African” and 1 as “Arabic”. At the time of the study the UK prevalence of
189 self-described white British ethnicity was 87.2%.¹²

190 Remarkable past ophthalmic and family history were as listed in table 2. None were
191 considered to be related to the new onset of the pit maculopathy. No participants
192 described any recent, clinically significant ocular trauma.

193 The maculopathy involved the fovea in 59 (84%) cases and 14 of the 70 cases
194 (20%) were asymptomatic. Visual acuity (Va) ranged from -0.04 to 2 logMAR with a
195 mean acuity of 0.54.

196 The mean spherical equivalent refractive error was -0.10 dioptres (SD 2.34, range -7
197 to +8).

198 A Weiss ring was present in 6 (9%) cases at baseline.

199 In 31 cases the right eye was affected, and in one case, bilateral disc pits were
200 present, however maculopathy was only present in one eye. The pit was located in
201 the temporal part of the disc in 37 cases, inferotemporally in 27, superotemporally in
202 2 and nasally in 2. The pit was larger than the standard picture in 42, smaller in 15,
203 and the same size in 13 cases. 2 cases had separate discrete choroidal colobomas
204 in the same eye.

205 The fluid distribution of the maculopathy was divided into 7 groups based on the
206 presence of subretinal fluid (SRF), inner retinal fluid (IRF) and outer retinal fluid
207 (ORF) (Table 3). 43 (61%) patients had SRF and 27 (39%) had intraretinal layer fluid
208 only. The number of participants with involvement of the foveal centre, the presence

209 of symptoms and the initial management relative to the presence or absence of SRF
210 is outlined in table 3.

211 At baseline, Va was significantly associated with foveal involvement ($P < 0.001$) and
212 foveal involvement was significantly related to the presence of symptoms ($p = 0.001$).

213 There was no significant association between pit size, patient age, foveal
214 involvement or retinal fluid type.

215

216 Patients with SRF had significantly worse vision at baseline than those without SRF
217 (mean Va with SRF = 0.76 (SD 0.57) versus mean Va without SRF = 0.36 (SD 0.35);
218 $p = 0.002$). The group with SRF and multi-layered intra-retinal fluid (MLF)
219 demonstrated the worst baseline Va of all the fluid types (mean Va = 0.79).

220

221 Treatment and clinical course

222 15 of the 70 (21%) patients with baseline data were initially treated by vitrectomy, 52
223 were observed only and 3 had a trial of a carbonic anhydrase inhibitor (CAI)
224 (delivered orally in 2 and topically in 1); this therapy did not result in anatomical or
225 visual improvement in any of the 3 patients. No patient had laser treatment alone.

226 Table 4 describes the features of the group who were initially observed or treated
227 with a CAI, compared with those who underwent primary vitrectomy. The group
228 undergoing primary vitrectomy had a worse baseline Va, more commonly had SRF,
229 and specifically, at baseline more often showed evidence of SRF with multi-layered
230 intraretinal fluid than the group who were initially observed.

231

232 Of the 55 patients who were observed or treated with a CAI, 53 had complete data 1-
233 year after baseline. 9 (17%) of these 53 patients showed evidence of anatomical

234 improvement on OCT, 10 (19%) worsened, and 34 (64%) were unchanged. At 1-
235 year follow-up, 10 of the 53 (19%) patients underwent vitrectomy (8 had evidence of
236 anatomical worsening and 2 had remained stable with reduced vision). The
237 relationship between the initial fluid distribution pattern and the clinical course is
238 shown in table 5, which describes all fluid distribution types, and table 6, which
239 describes the course relative to the presence or absence of SRF. When comparing
240 patients with SRF at baseline to those without SRF, those with SRF were more likely
241 to worsen (27% versus 9%) and less likely to improve (7% versus 30%, $p=0.04$) over
242 the 1-year follow up.

243 All 25 patients managed by vitrectomy (15 initial and 10 delayed) underwent
244 intraoperative posterior hyaloid face separation. A variety of other procedures were
245 performed: 9 (36%) patients had temporal juxtapapillary laser applied, 13 (52%) had
246 an internal limiting membrane (ILM) peel, 2 (8%) had SRF drainage, all but one had
247 gas tamponade (of which 5 (20%) was short acting gas (SF₆) and 19 (76%) long
248 acting gas (C₃F₈ or C₂F₆)), one (4%) had a ILM flap performed and 2 (8%) had an
249 inner retinal fenestration conducted. Anatomical outcomes were unrelated to
250 intraoperative juxtapapillary laser application ($p=0.18$), the use of gas ($p=0.99$), and
251 ILM peeling ($p=0.32$).

252

253 Following vitrectomy, 6 (24%) had persisting sub- or intraretinal fluid located at the
254 foveal centre when the study was completed. 4 (16%) had a worse Va, 6 (24%) had
255 stable vision and 15 (60%) had improved vision compared with measurements taken
256 immediately before surgery. Va at baseline and at 1-year follow-up is highlighted for
257 all groups with 1-year follow-up in table 7.

258

259 Five patients who underwent vitrectomy required revision vitrectomy surgery during
260 the course of this study; 4 of these were from the initial vitrectomy group, one of
261 whom experienced a vitreous cavity haemorrhage following revision vitrectomy and
262 required a further procedure, and one from the delayed vitrectomy group who
263 developed a rhegmatogenous retinal detachment. The other 3 were performed due
264 to initial treatment failure; 2 of these developed macular holes following surgery
265 which required a further procedure. Of these 2 patients one had an ILM peel during
266 the initial surgery and 1 had not.

267

268 **Discussion**

269 This is the first population-wide study of incident cases of ODPM. We present novel
270 data on the incidence, presenting features, and natural history of ODPM with and
271 without treatment, in an unbiased consecutive cohort over a two-year period using
272 an established and validated methodology.

273

274 Congenital ODPM has always been considered a rare condition and we confirmed
275 this with an incidence of approximately 1 per 2 million population per annum. We
276 asked ophthalmologists to report all incident cases presenting to them regardless of
277 symptoms and indeed 15 of our cases were asymptomatic, suggesting that the true
278 incidence may in fact be higher owing to non-presentation. Similarly, we may have
279 missed cases from failed reporting. The BOSU had a return rate of 76% during the
280 study period. Non-return could be due to both systematic and random factors,
281 although it is likely to be higher in clinicians who had not seen cases during the study
282 period. The rate reported therefore represents the minimum incidence, with a
283 likelihood of some under ascertainment, including 9 possible cases that were

284 unverified by questionnaire. Previous BOSU studies have reported a validated
285 ascertainment rate between 65% and 95%.¹⁰ If the 9 possible cases were true and
286 ascertainment were proportionate to the card return rate (76%), there would be an
287 estimated incidence of 109 cases over the two years, equivalent to approximately
288 8.1 per 10 million per annum. If ascertainment was equivalent to the lowest reported
289 rate (65%), incidence would be 9.5 per 10 million per annum.

290 The prevalence of congenital optic disc pits has been recorded in two population
291 level studies. The Blue Mountains eye study found a prevalence of 0.19% but only 1
292 of the 9 cases identified was likely congenital, providing a prevalence of
293 approximately 2 in 10,000.¹ Similarly, the Beijing eye study suggest a similar
294 prevalence of approximately 2 in 10,000. This involved a racially distinct population
295 which suggests that the prevalence of ODPM is similar in different populations.
296 Therefore a total number of 13,000 people with congenital pits in the UK may be
297 suggested.² It has previously been considered that approximately 25-75% of people
298 with congenital pits will develop maculopathy over their lifetime, which is in broad
299 agreement with our incidence figures.^{3, 9}

300

301 We found an equal sex incidence, a broad range of ages affected (mean 35 years),
302 and no clear racial or refractive predilection; this is consistent with previous reports.
303 Hence, our incidence figures are likely to be replicated across different countries,
304 regardless of demographic differences. Although we found some rare coexistent
305 conditions, no family history or personal coexisting disorders showed a clear
306 relationship with the ODPM.¹³⁻¹⁵ There was only one patient with bilateral pits but
307 only one of the eyes was affected by maculopathy. Bilateral disc pit maculopathy
308 would appear to be very rare, and similarly, so would hereditary cases. Two patients

309 had separate and discrete circumscribed choroidal colobomas in the affected eye
310 which has previous been reported to be associated with ODPM.¹⁶
311
312 93% of the pits were located in either the temporal or inferotemporal region of the
313 optic disc, which is a higher frequency than that found in previously published series
314 of pits without macular changes.^{3, 9} As the 2 patients with pits located nasally did not
315 have foveal involvement and we obtained no cases with central pits, it may be
316 suggested that temporal pits are more commonly associated with the development of
317 clinically significant maculopathy. Pit size was unrelated to patient age or severity of
318 the maculopathy; it appears that the size of the pit is not a good surrogate marker for
319 the size of the proposed defect in the lamina cribosa present in ODPM. Similarly, we
320 found no relationship between pit size and the fluid distribution type. Roy *et al*
321 reported the type of fluid distribution in ODPM from a non-consecutive series of 32
322 ODPM cases identified in clinical practice.¹⁷ They found that the two most common
323 fluid patterns were SRF with either ORF or MLF; this was contrary to prior studies
324 which reported more cases of SRF with ORF.^{17, 22} We found that SRF with MLF was
325 the most common presentation but that cases with intraretinal fluid only were also
326 common, as previously described but not widely noted.¹⁸⁻²⁰ These findings may be
327 due to the widespread availability of spectral domain OCT in current practice which
328 allows for the fluid's exact location to be delineated, as well as the specific
329 methodology used in our study. We asked for all cases to be reported rather than
330 only those that were referred for surgery or management decisions. Cases with
331 intraretinal fluid only are relatively common; those affected usually have good Va and
332 often are asymptomatic. Conversely cases with SRF only are rare, as described by
333 Imamura et al.²¹ The fluid distribution that we identified is supported by the schemata

334 proposed by *Roy et al.* This details that usually the fluid initially transits from the pit
335 into the outer retina and then spreads into either or both the subretinal space and
336 inner retina.¹⁷ Direct transit from the pit directly into the subretinal space or inner
337 retina is uncommon. In our study, cases with SRF and MLF had the worst visual
338 acuities, as may be expected based on both the disrupted retinal function and the
339 likelihood of greater chronicity. Previous studies have also suggested that they also
340 have a worse prognosis following surgical intervention.²²

341

342 We also found that cases with SRF at baseline were more likely to progress than
343 cases without SRF (27% versus 9%), and similarly, cases without SRF were more
344 likely to improve compared with those with SRF (30% versus 7%). Interestingly, 5 of
345 the cases without SRF with foveal involvement spontaneously developed dry foveas
346 on OCT. This may be related to the size of the putative lamina cribosa defect. It is
347 possible that small defects with intraretinal fluid accumulation only are more likely to
348 spontaneously close with changes in pit shape or, the recently described, intra-
349 papillary proliferations in the pit that have been visualised using high definition
350 OCT.^{23, 24} This is useful to guide clinical decision making. It is a widely held belief
351 that patients with ODPM usually get worse and only rarely improve; for that reason,
352 early surgery is often advocated.²⁵⁻³⁰ However, our data suggest that patients without
353 SRF (and usually good visual function) could be observed initially, whereas patients
354 with SRF (and usually reduced vision) rarely improve and achieve superior outcomes
355 with surgery. Primary surgery achieved a significant improvement in Va, whereas
356 deferred surgery did not. However, the gain in vision and final Va were very similar
357 between the primary and deferred surgery groups. This suggests that initial

358 observation at least did not affect the final visual outcome in those undergoing
359 surgery. (Table 7)

360

361 Our treatment results broadly mirror those described in previous studies.

362 Approximately 75% of the patients undergoing vitrectomy achieved an anatomically
363 dry fovea on OCT, and 60% had a greater than 0.1 logMAR improvement in Va post-
364 operatively compared with recordings made immediately before vitrectomy. All
365 patients underwent vitrectomy with posterior hyaloid face separation. We did not find
366 a significant benefit from ILM peeling, juxtapapillary laser or the use of gas, similar to
367 other recent studies, but the number of cases in our study is too small to be
368 conclusive, with a risk of type II errors.^{22, 31-35} Furthermore, 25 different surgeons
369 operated on the included cases without a defined therapeutic protocol, for example
370 for laser application and it is therefore not possible to draw definitive conclusions on
371 the benefit of particular surgical approaches. No surgeon opted to use scleral
372 buckling or gas injection without vitrectomy, reflecting the low adoption of these
373 procedures; this is an observation that others have made previously.^{7, 36} Similarly, no
374 patient underwent laser alone, an intervention used less frequently owing to its
375 variable efficacy.³⁷⁻³⁹ Three patients had a trial of CAIs, which have been reported to
376 result in visual improvement in some cases of OPDM, however it showed no
377 beneficial effect in this series.⁴⁰ It may be that CAIs only work in rare subtypes of
378 ODPM. Two patients underwent inner retinal fenestration and 2 had ILM flaps
379 performed. In all 4 of these cases, the interventions were performed in combination
380 with other procedures so the true efficacy of the individual manoeuvre is uncertain.
381 Ooto *et al* described a series of 18 eyes treated with inner retinal fenestration⁴¹; only
382 5 of these eyes had posterior hyaloid face separation induced, and no gas

383 tamponade or laser was used. Remarkable success was achieved in 17 cases but
384 unfortunately other attempts have been less successful and further study is
385 needed.⁴² The use of ILM flaps has been reported by some authors in ODPM cases
386 but similarly, further investigations are needed to determine the true efficacy.⁴² The
387 use of these novel approaches reflect the current suboptimal outcomes achieved in
388 the treatment of ODPM. This is also reflected by the diverse treatment approaches
389 that are adopted by different surgeons in the UK.

390

391 Two patients in our study developed full thickness macular holes after surgical
392 intervention. One patient underwent ILM peeling intraoperatively which has
393 previously been hypothesised as a risk factor for macular hole formation. We do not
394 know if either of these patients had evidence of an outer retinal defect at the fovea
395 preoperatively, which is another hypothesised risk factor. Certainly it is a
396 complication that patients should be counselled about.⁴³

397

398 Although a robust methodology was used in our study, it has several limitations. The
399 data for the study were obtained by using questionnaires that were completed by
400 independent ophthalmologists and as a result, the accuracy of the data returned to
401 the researchers cannot be validated. To maximise the accuracy of the data returned
402 and hence improve the reliability of this study's results, the questionnaire, including
403 the use of the standard pictures, was trialled and optimised before the onset of the
404 study. In addition, the response rate from the independent ophthalmologists was not
405 100%, however when compared with similar studies, the rate was high. We have
406 discussed the uncertainty concerning incidence calculations, however the frequency
407 of occurrence identified in our study concurs with what was expected, and therefore

408 can be considered as reasonably reliable. Follow-up was restricted to 1-year after
409 the patient initially presented or last intervention. More patients of the original cohort
410 may have gone onto vitrectomy, recurrences could have occurred, and Va in the
411 operated cases could have improved further with time. Our limited follow-up period
412 prevented the identification of these outcomes and future studies would ideally
413 monitor cases for a longer length of time.

414

415 In conclusion, we have identified the incidence of ODPM as approximately 1 in 2
416 million of the UK population per annum. The incidence showed no sex, age,
417 refractive or race predilection suggesting that the rate will be similar in other
418 countries. We have defined the case mix presenting to ophthalmologists, identifying
419 the relationship between symptoms, visual acuity and retinal fluid distribution and
420 differences in their progression. Finally, we have presented representative results of
421 surgery for an unselected consecutive cohort by a mixture of surgeons. Further
422 prospective studies on the management of this enigmatic condition are required.

423

424 **Acknowledgements:**

425 We are extremely grateful for the expert help and assistance given by the BOSU
426 Chairman and steering committee and Mr Barny Foot of the Royal College of
427 Ophthalmologists. We would also like to sincerely thank all the UK Ophthalmologists
428 who contributed cases to this study and for their assistance with questionnaire
429 completion and answering queries.

430

431 **References**

432

433 1 Healey PR, Mitchell P. The prevalence of optic disc pits and their relationship
434 to glaucoma. *J Glaucoma*. 2008;17(1):11-14.

435 2 Wang Y, Xu L, Jonas J. Prevalence of congenital optic disc pits in adult
436 Chinese: the Beijing eye study. *Eur J Ophthalmol*. 2006;16(6):863-864.

437 3 Brown GC, Shields JA, Goldberg RE. Congenital pits of the optic nerve head:
438 II. Clinical studies in humans. *Ophthalmology*. 1980;87(1):51-65.

439 4 Kranenburg EW. Crater-like holes in the optic disc and central serous
440 retinopathy. *Arch Ophthalmol*. 1960;64(6):912-924.

441 5 Irvine AR, Crawford JB, Sullivan JH. The pathogenesis of retinal detachment
442 with morning glory disc and optic pit. *Trans Am Ophthalmol Soc*. 1986;84:280-
443 292.

444 6 Christoforidis JB, Terrell W, Davidorf FH. Histopathology of optic nerve pit-
445 associated maculopathy. *Clin Ophthalmol* 2012;6:1169-1174.

446 7 Jain N, Johnson MW. Pathogenesis and treatment of maculopathy associated
447 with cavitory optic disc anomalies. *Am J Ophthalmol*. 2014;158(3):423-435.

448 8 Georgalas I, Ladas I, Georgopoulos G, Petrou P. Optic disc pit: a review.
449 *Graefes Arch Clin Exp Ophthalmol*. 2011;249(8):1113-1122.

450 9 Gordon R, Chatfield R. Pits in the optic disc associated with macular
451 degeneration. *Br J Ophthalmol*. 1969;53(7):481-489.

452 10 Foot B, Stanford M, Rahi J, Thompson J. The British Ophthalmological
453 Surveillance Unit: an evaluation of the first 3 years. *Eye*. 2003;17(1):9-15.

454 11 Office for National Statistics. Population estimates for UK, England and
455 Wales, Scotland and Northern Ireland: mid-2015.
456 <https://www.ons.gov.uk/peoplepopulationandcommunity/populationandmigrati>

457 [on/populationestimates/bulletins/annualmidyearpopulationestimates/mid2015/](http://www.irs.gov/populationestimates/bulletins/annualmidyearpopulationestimates/mid2015/)
458 ; 2016 Accessed 03.09.17.

459 12 Institute of Race Relations. Ethnicity and Religion Statistics.
460 <http://www.irs.org.uk/research/statistics/ethnicity-and-religion/>; 2018
461 Accessed 06.01.18.

462 13 Slusher MM, Weaver RG, Greven CM, Mundorf TK, Cashwell LF. The
463 spectrum of cavitory optic disc anomalies in a family. *Ophthalmology*.
464 1989;96(3):342-347.

465 14 Stefko ST, Campochiaro P, Wang P, Li Y, Zhu D, Traboulsi EI. Dominant
466 inheritance of optic pits. *Am J Ophthalmol*. 1997;124(1):112-113.

467 15 Jonas JB, Freisler KA. Bilateral congenital optic nerve head pits in
468 monozygotic siblings. *Am J Ophthalmol*. 1997;124(6):844-846.

469 16 Apple DJ. New aspects of colobomas and optic nerve anomalies. *Int*
470 *Ophthalmol Clin*. 1984;24(1):109-121.

471 17 Roy R, Waanbah AD, Mathur G, Raman R, Sharma T. Optical coherence
472 tomography characteristics in eyes with optic pit maculopathy. *Retina*.
473 2013;33(4):771-775.

474 18 Krivoy D, Gentile R, Liebmann JM, Stegman Z, Walsh JB, Ritch R. Imaging
475 congenital optic disc pits and associated maculopathy using optical coherence
476 tomography. *Arch Ophthalmol*. 1996;114(2):165-170.

477 19 Rutledge BK, Puliafito CA, Duker JS, Hee MR, Cox MS. Optical coherence
478 tomography of macular lesions associated with optic nerve head pits.
479 *Ophthalmology*. 1996;103(7):1047-1053.

480 20 Hotta K, Hirakata A, Hida T. Retinoschisis associated with disc coloboma. *Br*
481 *J Ophthalmol*. 1999;83(1):124.

- 482 21 Imamura Y, Zweifel SA, Fujiwara T, Freund KB, Spaide RF. High-resolution
483 optical coherence tomography findings in optic pit maculopathy. *Retina*.
484 2010;30(7):1104-1112.
- 485 22 Steel DH, Williamson TH, Laidlaw DAH, Sharma P, Matthews C, Rees J, et al.
486 Extent and location of intraretinal and subretinal fluid as prognostic factors for
487 the outcome of patients with optic disk pit maculopathy. *Retina*.
488 2016;36(1):110-118.
- 489 23 Maertz J, Mohler KJ, Kolb JP, Kein T, Neubauer A, Kampik A, et al.
490 Intrapapillary proliferation in optic disk pits: clinical findings and time-related
491 changes. *Retina*. 2017;37(5):906-914.
- 492 24 Pinarci EY, Karacal H, Oncel B, Bayar SA, Karakaya M. The inner diameter of
493 the optic disc pit decreases with pars plana vitrectomy. *Int Ophthalmol*.
494 2013;33(2):199-201.
- 495 25 Sugar HS. Congenital Pits in the Optic Disc: And Their Equivalents
496 (Congenital Colobomas and Colobomalike Excavations) Associated by
497 Submacular Fluid. *Am J Ophthalmol*. 1967;63(2):298-307.
- 498 26 Sobol WM, Blodi CF, Folk JC, Weingeist TA. Long-term visual outcome in
499 patients with optic nerve pit and serous retinal detachment of the macula.
500 *Ophthalmology*. 1990;97(11):1539-1542.
- 501 27 Patton N, Aslam SA, Aylward G. Visual improvement after long-standing
502 central serous macular detachment associated with an optic disc pit. *Graefes*
503 *Arch Clin Exp Ophthalmol*. 2008;246(8):1083-1085.
- 504 28 Tripathy K. Spontaneous resolution of optic disc pit maculopathy. *Turk J*
505 *Ophthalmol*. 2017;47(3):184-185.

- 506 29 Bayar SA, Sezenöz AS, Pınarcı EY, Yılmaz G. Spontaneous regression of
507 optic disc pit maculopathy in a six-year-old child. *Turk J Ophthalmol*.
508 2017;47(1):56-58.
- 509 30 Yuen CH, Kaye SB. Spontaneous resolution of serous maculopathy
510 associated with optic disc pit in a child: a case report. *J AAPOS*.
511 2002;6(5):330-331.
- 512 31 Avcı R, Kapran Z, Ozdek Ş, Teke M, Oz O, Guven D, et al. Multicenter study
513 of pars plana vitrectomy for optic disc pit maculopathy: MACPIT study. *Eye*.
514 2017;31(9):1266-1273.
- 515 32 Rayat JS, Rudnisky CJ, Waite C, Huang P, Sheidow TG, Kherani A, et al.
516 Long-term outcomes for optic disk pit maculopathy after vitrectomy. *Retina*.
517 2015;35(10):2011-2017.
- 518 33 Abouammoh MA, Alsulaiman SM, Gupta VS, Mousa A, Hirakata A, Berrocal
519 MH, et al. Pars plana vitrectomy with juxtapapillary laser photocoagulation
520 versus vitrectomy without juxtapapillary laser photocoagulation for the
521 treatment of optic disc pit maculopathy: the results of the KKESH International
522 Collaborative Retina Study Group. *Br J Ophthalmol*. 2016;100(4):478-483.
- 523 34 Hirakata A, Inoue M, Hiraoka T, McCuen BW. Vitrectomy without laser
524 treatment or gas tamponade for macular detachment associated with an optic
525 disc pit. *Ophthalmology*. 2012;119(4):810-818.
- 526 35 Teke MY, Citirik M. 23 gauge vitrectomy, endolaser, and gas tamponade
527 versus vitrectomy alone for serous macular detachment associated with optic
528 disc pit. *Am J Ophthalmol*. 2015;160(4):779-785.

- 529 36 Moisseiev E, Moisseiev J, Loewenstein A. Optic disc pit maculopathy: when
530 and how to treat? A review of the pathogenesis and treatment options. *Int J*
531 *Retina Vitreous*. 2015;1(1):13.
- 532 37 Bonnet M. Serous macular detachment associated with optic nerve pits.
533 *Graefes Arch Clin Exp Ophthalmol*. 1991;229(6):526-532.
- 534 38 Mustonen E, Varonen T. Congenital pit of the optic nerve head associated
535 with serous detachment of the macula. *Acta Ophthalmol*. 1972;50(5):689-698.
- 536 39 Brockhurst R. Optic pits and posterior retinal detachment. *Trans Am*
537 *Ophthalmol Soc*. 1975;73:264-291.
- 538 40 Prakash P, De Salvo G, Lotery A. Morning glory with serous macular
539 detachment responds to oral acetazolamide. *Eye*. 2010;24(11):1732-1733.
- 540 41 Ooto S, Mitra RA, Ridley ME, Spaide RF. Vitrectomy with inner retinal
541 fenestration for optic disc pit maculopathy. *Ophthalmology*. 2014;121(9):1727-
542 1733.
- 543 42 Hara R, Tsukahara Y, Simoyama T, Mori S. Refined Internal Limiting
544 Membrane Inverted Flap Technique for Intractable Macular Detachment with
545 Optic Disc Pit. *Case Rep Ophthalmol* 2017;8(1):208-213.
- 546 43 Shukla D, Kalliath J, Tandon M, Vijayakumar B. Vitrectomy for optic disk pit
547 with macular schisis and outer retinal dehiscence. *Retina*. 2012;32(7):1337-
548 1342.

549

550

551 **Legends**

552 **Figure 1:**

553 Representative horizontal spectral domain optical coherence tomography images of
554 optic disc pit maculopathy cases. (a) Patient with multilayer intraretinal fluid and
555 subretinal fluid: inner retinal layer fluid (short arrow), outer retinal layer fluid (long
556 arrow) and an outer retinal defect with subretinal fluid (broad arrow). (b) Outer retinal
557 layer fluid only (long arrow). (c) Subretinal fluid only (broad arrow). (d) Non-foveal
558 fluid involving outer retinal layer fluid only. (e) Multilayer intraretinal fluid involvement
559 with outer retinal defect and subretinal fluid. (f) Colour fundal photograph of optic
560 disc with 'reference' optic disc pit used in the study for size comparison purposes.

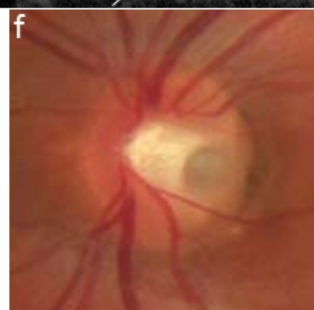
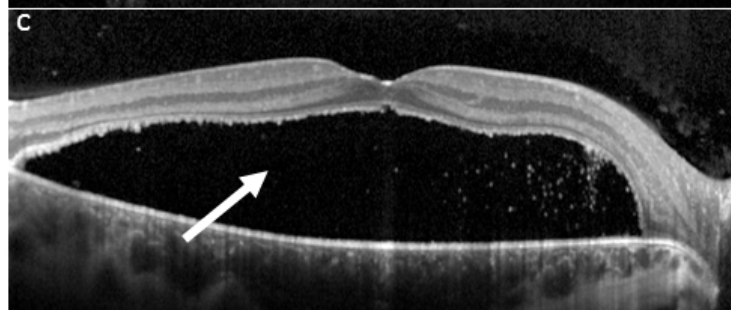
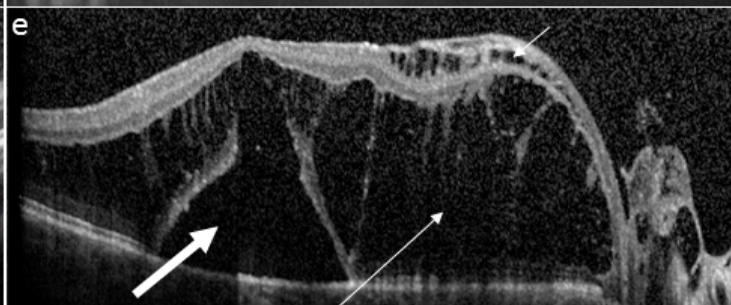
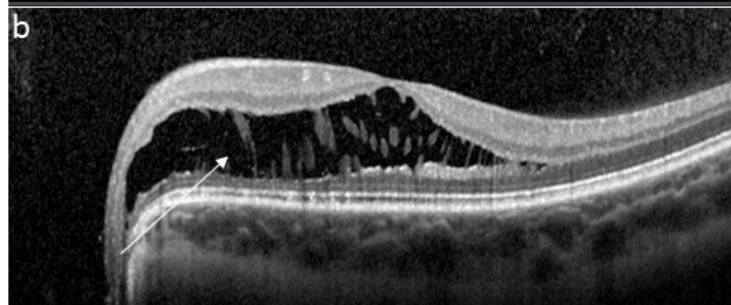
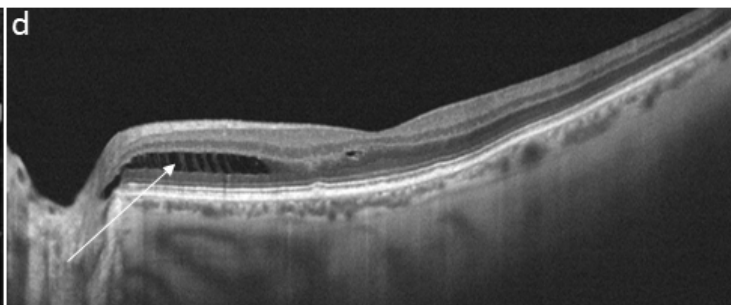
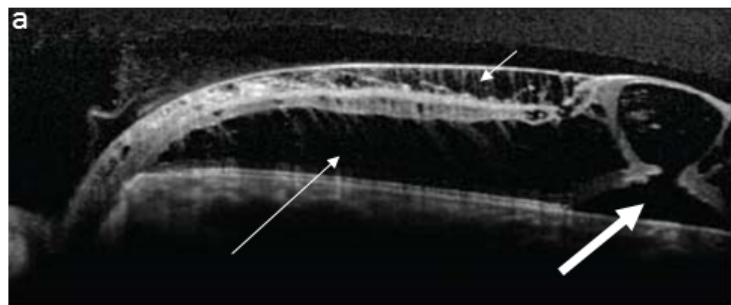


Table 1: Baseline features

Variable	Number (n=70 unless stated otherwise)
Age in years: mean; SD; range	35; 22.1; 3-82
Sex	Male: 35 (50%) Female: 35 (50%)
Laterality	Right: 31 (44%) Left: 39 (56%)
Refraction (spherical equivalent) in dioptres: mean; standard deviation; range <i>(Data missing in 29)</i>	-0.10; 2.3; -7 to +8
Symptoms present	Yes: 56 (77%) No: 14 (20%)
Visual acuity (logMAR): mean; SD; range	0.61; 0.54; -0.04 - 2.0
Position of pit on optic disc	Temporal: 37 (53%) Inferotemporal: 28 (40%) Superotemporal: 2 (3%) Nasal: 2 (3%)
Size of pit relative to standard picture: Smaller/Same/Larger	Smaller: 15 (21%) Same size: 13 (19%) Larger: 42 (60%)
Foveal involvement	Yes: 59 (84%) No: 11 (16%)
Presence of SRF	Yes: 43 (61%) No: 27 (39%)
Presence of PVD	Yes: 6 (9%) No: 64 (91%)
Initial management (Observation/vitrectomy)	Observation: 55 (79%) Vitrectomy: 15 (21%)
Delayed secondary vitrectomy	10 (14%)

SD: standard deviation, PVD: posterior vitreous detachment, SRF: subretinal fluid

Table 2: Past ophthalmic history and family history

Past ophthalmic history and family history	Number of cases
Cataract surgery (several years previously)	1
Photodynamic therapy for a choroidal neovascular membrane secondary to presumed ocular histoplasmosis syndrome in the fellow eye (several years previously)	1
Peripheral iridectomies for acute angle-closure glaucoma (several years previously)	1
Orbital rim fracture (40+ years previously with normal vision prior to the ODPM)	1
Known occipital infarcts (but normal central acuities prior to the ODPM)	1
Amblyopia in affected eye (one with associated microphthalmia)	3
Known Ehlers-Danlos syndrome	1
Identical twin brother with open-angle glaucoma (but no optic disc pit)	1
Brother with a hereditary cone dystrophy	1

Table 3: Retinal fluid distribution at baseline.

	Fluid distribution type (n=70)	Number of cases	Foveal centre involved	Symptomatic at baseline	Initial management by vitrectomy
SRF absent: N=27 (39%)	IRF only	1 (1%)	19 (70%)	16 (59%)	2 (7%)
	ORF only	15 (21%)			
	IRF and ORF only	11 (16%)			
SRF present: N=43 (61%)	SRF and ORF only	9 (13%)	40 (93%) (p=0.009)	40 (93%) (p=0.002)	13 (30%) (p=0.007)
	SRF and IRF only	3 (4%)			
	SRF and IRF and ORF	26 (37%)			
	SRF only	5 (7%)			

IRF: Inner retinal fluid, ORF: Outer retinal fluid, SRF: subretinal fluid

Table 4: Comparison of baseline features between those undergoing primary vitrectomy and those managed by observation.

Features (n=70)	Initial vitrectomy (n=15)	Observation (n=55)	P-value
Age in years mean; SD	42.2; 13.4	33.1; 22.7	p=0.08
Sex (male/female)	Male: 10 (67%) Female: 5 (33%)	Male: 25 (45%) Female: 30 (55%)	p=0.24
Foveal involvement (Yes/No)	Yes: 15 (100%) No: 0 (0%)	Yes: 44 (80%) No: 11 (20%)	p=0.11
Symptoms (Yes/No)	Yes: 14 (93%) No: 1 (7%)	Yes: 38 (69%) No: 15 (31%)	p=0.10
logMAR visual acuity: mean; SD	0.92; 0.52	0.53; 0.51	p=0.01
Fluid distribution	Intraretinal fluid only: 2 (13%) SRF +MLF: 10 (67%) SRF +/- ORL or IRL: 3 (20%)	Intraretinal fluid only: 25 (45%) SRF +MLF: 16 (30%) SRF +/- ORL or IRL: 14 (25%)	p=0.02
SRF presence (Yes/No)	Yes: 13 (87%) No: 2 (13%)	Yes: 30 (55%) No: 25 (45%)	p=0.04

IRF: Inner retinal fluid, ORF: Outer retinal fluid, SRF: subretinal fluid, MLF: multilayer intra-retinal fluid, SD: standard deviation.

Statistically significant p-values shown in bold.

Table 5: Changes in amount of retinal fluid in the patients initially observed with complete data 1-year after the initial presentation, subdivided according to the initial fluid distribution.

Fluid extent changes after initial observation (N=53)	IRF only (N=1)	ORF only (N=12)	ORF + IRF only (N=10)	SRF + IRF + ORF (N=16)	SRF + ORF (N=6)	SRF +IRF (N=3)	SRF only (N=5)
Fluid same	1	6	7	12	3 (*1)	2	3 (*1)
Fluid worse	0	1	1*	4 (*3)	2*	1*	1*
Fluid better	0	5	2	0	1	0	1

ORF: outer retinal fluid, IRF: inner retinal fluid, SRF: subretinal fluid

*Signifies number of those having a deferred vitrectomy

Table 6: Changes in amount of retinal fluid in the patients initially observed divided up by the presence of SRF at baseline

Anatomical change in amount of retinal fluid observed on OCT	No SRF (n=23)	SRF (n=30)
Same	14 (61%)	21 (70%)
Worse	2 (9%)	8 (27%)
Better	7 (30%)	2 (7%)

*p=0.04(Fishers exact test)

Table 7: Visual outcomes

	Subgroups	Baseline visual acuity (logMAR) Mean, SD	Final visual acuity (logMAR) Mean, SD	Difference (final-baseline)	p-value
Entire Cohort	Entire cohort with 1-year follow-up (n=68)	0.62, 0.54	0.59, 0.53	-0.03	0.57
Observed Cases	Observed throughout study (n=43)	0.49, 0.49	0.55, 0.58	0.06	0.18
	Observed – no SRF at baseline (n=23)	0.33, 0.33	0.31, 0.42	-0.02	0.71
	Observed – SRF at baseline (n=20)	0.69, 0.58	0.75, 0.57	0.06	0.40
Cases Undergoing Vitrectomy	Primary vitrectomy (n=15)	0.92, 0.52	0.70, 0.43	-0.22	0.05
	Deferred vitrectomy (n=10)	At baseline: 0.70, 0.60 Immediately prior to vitrectomy: 0.87, 0.51	0.64, 0.51	-0.06 -0.23	0.78 0.32
	All vitrectomy (n=25)	0.83, 0.57	0.67, 0.46	-0.16	0.14

*For vitrectomy patients, baseline visual acuity is given as visual acuity immediately before vitrectomy.
Mean, SD and range are given for all.